



VCU

Virginia Commonwealth University
VCU Scholars Compass

Theses and Dissertations

Graduate School

2019

THE EFFICACY OF A FLUORIDE-CONTAINING ORTHODONTIC PRIMER IN PREVENTING DEMINERALIZATION

Alyssa G. Ricci
Virginia Commonwealth University

Follow this and additional works at: <https://scholarscompass.vcu.edu/etd>



Part of the [Dental Materials Commons](#), and the [Orthodontics and Orthodontology Commons](#)

© The Author

Downloaded from

<https://scholarscompass.vcu.edu/etd/5789>

This Thesis is brought to you for free and open access by the Graduate School at VCU Scholars Compass. It has been accepted for inclusion in Theses and Dissertations by an authorized administrator of VCU Scholars Compass. For more information, please contact libcompass@vcu.edu.

© Alyssa Gutierrez Ricci, DDS 2019

All Rights Reserved

THE EFFICACY OF A FLUORIDE-CONTAINING ORTHODONTIC PRIMER IN
PREVENTING DEMINERALIZATION

A thesis submitted in partial fulfillment of the requirements for the degree of Master of Science
in Dentistry at Virginia Commonwealth University.

By

Alyssa Gutierrez Ricci

B.S. in Food Science and Human Nutrition from University of Florida, May 2013

D.D.S. from Virginia Commonwealth University, May 2017

Thesis advisor: Dr. Eser Tüfekci, D.D.S., M.S., Ph.D., M.S.H.A.

Professor, Department of Orthodontics

Virginia Commonwealth University

Richmond, Virginia

May 2019

Acknowledgements

I want to thank my research mentor Dr. Eser Tufekci for all of her guidance, encouragement, and support not only with this project, but in my life for the past four and a half years. I know Dr. Tufekci will be a mentor and friend forever, and I am so grateful for her.

I want to thank Dr. Parthasarathy Madurantakam for his help with this project and unwavering support over the past five and a half years. He was my mentor throughout dental school and has never stopped supporting me.

I would like to acknowledge Dr. D. Joshua Cohen for all of his work in obtaining micro-CT images of the samples. He has taught me so much and his expertise has been invaluable.

I am beyond grateful for the help of Dr. Caroline Carrico, the best statistician and most caring and humble individual. I couldn't have done this without her.

I need to extend a very special thank you to Ryan Depew, fourth year dental student and future orthodontist, and Alix Kloster, future dentist, for all of their help and hard work on this project.

I want to thank all of my co-residents for their help and support. This study would not have been possible without them.

I also want to thank Dr. Steven Lindauer and Dr. Bhavna Shroff for their advice and encouragement not only in regards to this project, but throughout my entire residency. I am blessed to have such intelligent and supportive professors.

It is important to me to acknowledge my parents, Andres and Teresita Gutierrez, for sacrificing so much to give me and my sister everything they couldn't have. They are my biggest inspirations and a true example of hard work, determination, and humility. I wouldn't be where I am today without them. I love them so much.

Last but not least, I want to thank my incredible husband, Jonathan Ricci, for his unconditional love and support throughout life. He is my best friend of 12 years and my number one fan. He has provided for our family while I have been in school, and he has made me countless exceptional dinners while I am up late doing work. He has also made it possible for me to have my beautiful horse, Promise Ricci, who is my escape after a crazy day and my pride and joy in life. I can't imagine my life without him. He is my forever.

Table of Contents

Acknowledgements.....	ii
Table of Contents.....	iii
List of Tables.....	iv
List of Figures.....	v
Abstract.....	vi
Introduction.....	1
Methods.....	5
Results.....	10
Discussion.....	12
Conclusion.....	16
References.....	26

List of Tables

Table 1: Association between Patient Factors and Presence of Lesion	17
Table 2: Summary of Lesion Depth for Each Study Subject.....	17
Table 3: Summary of Lesion Depth by Treatment	18

List of Figures

Figure 1: Patient Enrollment and Final Sample Size	19
Figure 2: Research Participant Questionnaire.....	20
Figure 3: 3D Micro-CT Images of a Sample of Teeth with Enamel Demineralization. Surface roughness can be visualized.....	21
Figure 4: 2D Micro-CT Images of a Sample of Teeth with Enamel Demineralization. Axial slice of the deepest lesion that was measured for these two samples can be seen.	22
Figure 5: Photographs of a Sample of Teeth that Developed White Spot Lesions.....	23
Figure 6: Methods Workflow.....	24
Figure 7: Summary of Lesion Depth for Each Study Subject	25

Abstract

THE EFFICACY OF A FLUORIDE-CONTAINING PRIMER IN PREVENTING DEMINERALIZATION

By: Alyssa G. Ricci, DDS

A thesis submitted in partial fulfillment of the requirements for the degree of Master of Science in Dentistry at Virginia Commonwealth University.

Virginia Commonwealth University, 2019

Thesis Advisor: Eser Tüfekci, D.D.S., M.S., Ph.D., M.S.H.A.
Professor, Department of Orthodontics

Purpose: To evaluate the efficacy of a fluoride-containing orthodontic primer in preventing demineralization adjacent to brackets and compare the quality of enamel on tooth surfaces that received interproximal reduction (IPR).

Methods: Patients at the VCU Orthodontic clinic who consented to orthodontic treatment involving extraction of at least 2 premolars were recruited to this pilot clinical study. Brackets were bonded to premolars using one of two primers, fluoride-containing experimental or control. IPR was also performed, and the experimental primer was applied to randomly selected teeth. Extracted teeth were analyzed visually for the presence of white spot lesions (WSLs). Micro-CT analyses were also performed to evaluate demineralization and measure the lesions.

Results: A total of 18 teeth from 6 subjects were included in the following analyses. Based on micro-CT imaging, lesions were found on 89% of teeth treated with the experimental primer compared to 67% with the control primer, but this difference was not statistically significant

($p=0.5765$). There was also no significant difference between the depths of the lesions ($p=1.00$), handedness ($p=0.5765$), hygiene ($p=0.7804$), or time in the mouth ($p=0.5601$). According to visual examination, there was no significant difference in the incidence of WSLs between the two groups (89% and 89%; $p=1.00$) Also, there was no association with treatment ($p=1.00$), handedness ($p=1.00$), hygiene ($p=0.1373$), or time in the mouth ($p=0.2987$). No differences were noted on the microstructural characteristics of enamel at the IPR sites.

Conclusion: Fluoride-containing primers do not seem to provide any additional benefit over conventional non-fluoride primers in orthodontic patients.

Introduction

The number of people undergoing orthodontic treatment over the years has increased. According to the American Association of Orthodontists, more than 5 million people are treated with fixed appliances in a given year. Treatment of dental malocclusions with brackets brings the risk of developing white spot lesions (WSLs) on teeth in patients with poor oral hygiene.¹ Therefore, the formation of WSLs is a significant concern in orthodontics. Proper home care during orthodontic treatment takes extra time and effort on the patient's part as fixed appliances make it more difficult to adequately clean teeth.¹⁻⁶

WSLs, which represent the beginning stages of caries,^{2,4,7} may form as early as 4 weeks after the brackets are placed on teeth.⁶ The lesions appear white, chalky, and opaque, and therefore, they can make the end result of orthodontic therapy unesthetic.^{5,7} According to Gorelick et al⁴, about 50% of patients develop at least one white spot lesion by the end of their orthodontic treatment. Similarly, Hadler-Olsen et al.⁸ reported that 60% of their patients developed one or more WSLs. In another study,⁹ the incidence was reported to be as great as 73%. Therefore, it is because of the high incidence and prevalence that WSLs remain to be a significant problem that requires attention.

The preventive effect of fluoride in the form of varnishes, gels, cements, and rinses has been well-documented.¹⁰⁻¹³ Daily rinsing with 0.05% sodium fluoride mouthrinse has been

shown to reduce the severity and incidence of WSLs.¹⁴ There is also moderate evidence that the application of fluoride varnish every 6 weeks reduces the incidence of WSLs by 70%.¹² A study by Todd et al. found that the application of fluoride varnish in orthodontic patients can reduce enamel demineralization by 50%.¹⁵ Farhadian et al. found that the depth of demineralization was decreased by 40% in teeth that received fluoride varnish during orthodontic treatment.¹¹ The current recommendation by the American Dental Association for caries prevention in 6-18 year olds is the use of 0.09% fluoride mouthrinse at least weekly and the application of 2.26% fluoride varnish at least every 3-6 months or 1.23% fluoride (AFP) gel for 4 minutes at least every 3-6 months by a dental professional.¹⁶ Lately, studies have been focusing on the efficacy of fluoride delivery systems that do not rely on patient compliance, such as the application of a resin sealant to enamel to reduce demineralization in orthodontic patients. Previous research has shown that chemically cured sealants do not effectively seal the enamel surface due to oxygen inhibition of polymerization.¹⁷⁻¹⁹ However, light-cured sealants, although still susceptible to some oxygen inhibition, reach a higher degree of polymerization, and therefore better protect smooth enamel surfaces and prevent demineralization in vitro.^{19,20} In more recent studies, unfilled and lightly filled resins have been shown to be effective in vitro, but not when applied clinically.^{21,22} Furthermore, sealants with less filler content with low viscosity and high flowability properties exhibit reduced strength and retention rate. However, new generation sealants with high filler content have been shown to resist toothbrush abrasion and to effectively reduce demineralization because of their excellent surface retention and durability.²³

Recently, a fluoride-containing primer, Opal®Seal™ (Ultradent Products Inc., South Jordan, UT), has been introduced to the orthodontic market. It is claimed by the manufacturer that the primer prevents demineralization because it releases and recharges fluoride.²⁴ In addition,

Opal®Seal™ is marketed as a durable material. The long-lasting strength of the product is attributed to its high filler content that consists of 38% glass ionomer fillers plus nanofillers.

Previous clinical research²⁵ showed that there is a significant reduction in WSLs in teeth treated with Opal®Seal™ when teeth were observed before 90 days in vivo. In that study, teeth were extracted approximately 8 weeks after the primer application, and tooth surfaces were analyzed visually for both demineralization and primer retention. Because visual examination technique is somewhat subjective, demineralization was also assessed with microhardness testing. However, with the 25µm indentation depth, it was not possible to detect the shallow lesions that were less than the testing increment. In a more recent animal study, Opal®Seal™ has been shown to significantly reduce the erosive attack of acidic beverages.²⁶

Fluoride in the form of varnishes is also used to prevent the possible side effects of interproximal reduction (IPR). IPR is a common procedure carried out during orthodontic treatment to slightly reduce the mesial-distal width of teeth to alleviate crowding and size discrepancies. While some studies report no long term adverse effects of interproximal reduction,²⁷ others indicate that IPR roughens the enamel surface making it more plaque-retentive,²⁸ and therefore, more susceptible to demineralization. According to Giulio et al.²⁸, teeth treated with IPR undergo greater demineralization when exposed to acidic environments when compared with teeth that haven't been subjected to this procedure. Although polishing the enamel surface after IPR is a common practice that has been shown to be beneficial, it has been reported that polishing does not significantly reduce the amount of demineralization seen on the treated teeth.²⁹ Furthermore, the topical application of casein phosphopeptide-amorphous calcium phosphate (CPP-ACP) has also been shown to promote enamel remineralization after IPR.²⁸ However, the efficiency of CPP-ACP depends on patient compliance. Therefore, it would

be beneficial to have a fluoride releasing agent that could be professionally applied without the need for patient compliance.

Currently, there is limited information on the efficacy of fluoride-containing primers in protecting enamel against demineralization. Therefore, the purpose of this pilot clinical study was to evaluate the efficacy of a fluoride-containing orthodontic primer, Opal®Seal™, in preventing demineralization adjacent to brackets and on interproximal tooth surfaces that received interproximal reduction.

Methods

This study was approved by the Institutional Review Board at Virginia Commonwealth University (VCU). Patients at the VCU Orthodontic Clinic, 10 years and older, who had consented to orthodontic treatment involving extraction of at least 2 premolars were identified. Inclusion criteria were as follows: 1) good overall health, and 2) fully erupted and intact premolars without visible defects, demineralization, and fluorosis. Patients who fit the inclusion criteria were recruited to the study. Upon completion of the study, patients were compensated.

Thirteen patients agreed to participate in this study, but four patient had to drop out because there was a change in the treatment plan that called for either different teeth to be extracted, teeth to no longer be extracted, or teeth to not be extracted yet. The end result was 9 total patients that completed the study. Four patients had both upper and lower sets of premolars included; therefore, maxillary and mandibular teeth were counted as separate samples. There was a total of 13 sets of premolars included in this study (experimental and control), for a total of 26 teeth. 18 teeth underwent micro-CT and visual analysis for white spot detection, while a cohort of 5 experimental teeth were randomly selected to undergo fluorescence testing to determine retention (Figure 1).

In this split-mouth study, the interventions (Opal[®]Seal[™] or Transbond[™]XT) were performed by one of six calibrated residents. Teeth were randomized using a computer generated

random assignment table. Apart from the intervention, patients were treated the same way they would be if not participating in research. All patients were given oral hygiene instructions and had no additional appointments for research purposes.

At enrollment, subjects also completed a short, multiple-choice paper survey to help account for potential confounding variables that could otherwise affect the results of the study (Figure 2).

Prior to the bonding, IPR was performed on premolars planned for extraction to evaluate the therapeutic effect, if any, of the fluoride primer. This procedure was only done on the mesial and distal surfaces of the premolars, using one-sided handheld diamond-coated abrasive strips (Gateway, Brasseler, Savannah, GA). A fine strip was first used to break the interproximal contacts, followed by 25 back and forth strokes using firm pressure with a medium strip. These strips are routinely used in clinical practice when the goal is to reduce less than 200µm of enamel from one tooth surface.

Following the IPR procedure, bonding was carried out by cleaning off any plaque or debris, etching the enamel surface with phosphoric acid etch (GelEtch, Temrex, Freeport, NY), applying a primer (Opal®Seal™ or Transbond™XT), and finally attaching the bracket (OmniArch, DENTSPLY GAC, Islandia, NY or Mini Master®, American Orthodontics, Sheboygan, WI) onto the tooth with a light-cure resin adhesive (Transbond™XT, 3M Unitek, Monrovia, CA). As previously determined by the randomization schedule, one premolar received an application of Opal®Seal™ while the contralateral tooth surface was prepared with Transbond™XT (3M Unitek, Monrovia, CA).

Bonding was carried out using the standard clinical methods by previously calibrated residents. Opal®Seal™ was applied following manufacturer's instruction, where a thin even layer was placed onto the tooth surface with a disposable brush tip. The enamel was then lightly air dried for 2 seconds and light-cured for 5 seconds. The same procedure was followed when applying Opal®Seal™ to the interproximal surfaces that were treated with IPR.

Patients were asked to schedule the extraction appointment with the dentist/oral surgeon of their choice and were given a referral letter with instructions and labeled plastic jars filled with distilled water. Clinicians were instructed to attempt to keep the bracket in place when extracting the tooth. The jars containing extracted teeth at the follow-up appointment were collected by study personnel for disinfection. All specimens were cleaned of debris and then transferred into 0.5% chloramine T hydrate solution for two weeks. After two weeks, the samples were transferred into a new labeled container with distilled water and stored until analysis. The new storage jars were labeled this time using a code to prevent bias during analyses.

Eighteen teeth were then examined with micro computed tomography (micro-CT) to quantify the mineral density of the teeth. All scans were conducted on a Bruker Skyscan 1173 MicroCT, hardware version A at a resolution of 2240 x 2240 pixels (image pixel size of 7.91µm), with x-rays of 85kV and 93µA using a 1.0mm aluminum filter and exposure time of 1050 ms and a rotation step of 0.25°. Images were processed using Skyscan Control Software version 1.6 (Kontich, Belgium). Three dimensional (3D) images were analyzed using the CTvox software and depth measurements were obtained using DataViewer by two independent calibrated operators. Each operator scrolled through the slices from the middle third of the tooth to the cemento-enamel junction (CEJ) to locate the deepest part of the lesion, if a lesion was

noted on the 3D image (Figure 3). The slice number was recorded along with the depth measurement (in μm). The examiner then obtained depth measurements 5 slices above and 5 slices below this “deepest slice”. If one of the other slices resulted in a deeper lesion, then the examiner measured 5 slices above and below that particular slice. The deepest measurement recorded by each examiner was used for analyses. Figure 4 shows two-dimensional (2D) images of the deepest slice in a sample of teeth.

For the visual examination of white spot lesions, each tooth was individually removed from its storage bottle and air dried for 5 seconds. The buccal surface was then examined visually for enamel demineralization by two calibrated independent examiners using the following scale:³⁰

0: No visible white spots or surface disruption (no decalcification)

1: Visible white spot without surface disruption (mild decalcification)

2: Visible white spot with a roughened surface but not requiring restoration (moderate decalcification)

3: Visible WSL requiring restoration (severe decalcification)

The teeth were also photographed in controlled lighting with a Canon EOS Rebel T6 under the scene intelligent auto setting with flash (Figure 5).

Since Opal®Seal™ has a fluorescing agent in its composition, five randomly selected tooth surfaces were examined under a hand-held black light (Ultradent Products Inc., South Jordan, UT) to evaluate primer retention. The tooth surface was divided into 4 quadrants (mesiocclusal, distocclusal, mesioingival, and distoingival) and then further subdivided into 4 quadrants

within each quadrant. Therefore, the amount of remaining primer was recorded in each quadrant in increments of 6.25% if present in that quadrant. A score of 100% meant the whole tooth surface fluoresced under the black light, indicating full coverage, whereas a score of 0% indicated the complete absence of the material with no fluorescence in any of the quadrants.²⁵ Following the evaluation of primer retention, teeth were then examined with micro-CT imaging to quantify the mineral density of the teeth. The workflow of the methods is provided in Figure 6.

Statistical Analysis

Agreement between the two independent raters on the presence and severity of WSLs using micro-CT technique was assessed using Cohen's Kappa. Visual WSL ratings were further categorized into two groups with any rating of 0 indicating no lesion present and a rating 1-3 classified as present. Agreement of lesion presence between the two techniques was also evaluated using Cohen's Kappa.

A subset of teeth (n=5) that were assessed for primer retention were analyzed using descriptive statistics. The association between retention and time since bonding was assessed using Spearman's correlation.

Incidence of WSLs was compared based on treatment (experimental or control primer), right- or left-handedness, and oral hygiene using Fisher's Exact test based on both the visual exam and micro-CT. Lesion presence was also compared considering the time the teeth were in the mouth using Wilcoxon rank-sum test. Lesion depth measured by two independent raters was assessed for agreement using intraclass correlation coefficient (ICC). Depth was compared between teeth treated with the experimental and control primer using Wilcoxon Signed-Rank test to account for pairing within the same subject. Significance level was set at 0.05 for all analyses.

Results

A total of 18 teeth from 6 subjects were included in the following analyses, while 5 additional teeth were analyzed solely for retention. Of the 9 tooth surfaces that received the fluoride-containing primer, 7 received it on the same side and 2 on the opposite side of handedness, resulting in a significant relationship between handedness and randomization of the fluoride-containing primer ($p=0.0567$).

The average time from bonding to extraction was 108.2 days and ranged from 49 to 203. The retention of the fluoride-containing primer on the subset of 5 teeth evaluated ranged from 0 to 37.5, with a median of 28.1 and mean of 19.4. Retention was not significantly associated with the total time teeth were in the mouth. ($r=0.68$, $p=0.2362$).

Visual examination of demineralization demonstrated almost perfect intra-rater reliability ($k=0.92$; 95% CI: 0.82-1.00). The agreement between the two methods used to assess demineralization was fair ($k=0.22$). Three lesions found to be present using visual examination technique were not detected with micro-CT and one absent visually was assessed present with micro-CT. All 3 of the lesions that were deemed to be present using visual examination technique were rated as a “1” on the WSL criteria.

The presence of white spot lesions based on micro-CT analyses was perfectly matched between the two raters ($k=1$). The two operators also had near perfect agreement on both the location ($ICC=0.923$) and the depth of the deepest lesion ($ICC=0.924$).

Based on visual examination, presence of a WSL was not associated with treatment ($p=1.00$), right- or left-handedness ($p=1.00$), hygiene ($p=0.1373$), or the time the teeth were in the mouth ($p=0.2987$). Based on micro-CT analyses, there was still no significant association between lesion presence and intervention ($p=0.5765$), right- or left-handedness ($p=0.5765$), oral hygiene ($p=0.7804$), or time in the mouth ($p=0.5601$).

Depth of the lesion was also assessed based on the micro-CT data (Table 2, Figure 7). Using paired analysis, there was no statistically significant difference found between the depths of the lesions in the fluoride-containing primer group and the control group ($p\text{-value}=1.00$). There was a nearly equal split between subjects for which side had a deeper lesion: 5 (56%) had a deeper lesion on the side with the fluoride-containing primer compared to 4 (44%) with the control primer. The means, medians, and ranges are reported in Table 3.

The fluoride-containing primer also seemed to have no effect on the quality of the enamel on teeth subjected to IPR based on micro-CT analyses. No visible differences could be detected or measured when the enamel surfaces were evaluated.

Discussion

White spot lesions are a significant concern in orthodontic patients with poor oral hygiene, with 50% of patients developing at least one lesion by the end of their orthodontic treatment.⁴ Countless attempts have been made to try to prevent the formation of WSLs, but most rely on patient compliance. There is a need for a product that can be applied directly by the orthodontist to decrease the risk of developing these WSLs. This randomized controlled clinical trial sought to evaluate the efficacy of a fluoride-containing orthodontic primer, Opal[®]Seal[™], in preventing demineralization adjacent to brackets and on interproximal tooth surfaces that received interproximal reduction. Micro-CT imaging and visual examination analyses were used to evaluate enamel demineralization. Fluorescence testing was also utilized to determine retention of the fluoride-containing primer on the tooth surface.

In this study, based on visual examination technique, lesions were found to be present on 89% of teeth treated with the fluoride-containing primer as well as 89% of those treated with control primer ($p=1.00$). A previous clinical study by Tufekci et al.²⁵ also found no significant difference in the incidence of WSLs between the experimental and control groups. In that investigation, 29% of the experimental and 46% of the control teeth exhibited demineralization.

In the current project, there was also no statistically significant difference between right- or left-handedness and the corresponding quadrant between the two groups ($p=1.00$).

Interestingly, a previous study by London et al.³¹ reported that patients who were left-handed had a higher prevalence and severity of WSLs on their maxillary left incisors, while those who were right-handed experienced no difference on either side. However, previous studies^{32,33} reported no significant relationship between handedness and oral hygiene. Our results also confirmed the same findings.

Based on micro-CT analyses, lesions were found to be present on 89% of teeth treated with the fluoride-containing primer compared to 67% with the control primer, but this difference was not statistically significant ($p=0.5765$). These results were comparable to those of a study by Oz et al.,³⁴ which notes lesions in 60% of teeth treated with Opal®Seal™ compared to 80% of those treated with Transbond™XT, when analyzed under micro-CT imaging. There was also no statistically significant difference found between the depths of the lesions in either our study (p -value=1.00) study or the study by Oz et al. ($p>0.05$).

It was somewhat surprising to note that there was a difference in the results of incidence between micro-CT imaging and visual techniques used to determine demineralization. This could be partly due to the fact that soft demineralized enamel was likely taken off when removing the adhesive from the tooth surfaces during the sample preparation procedure prior to micro-CT analyses.

In the current study, the amount of primer remaining on the tooth surface was approximately 20%. According to the study by Tufekci et al.²⁵, the retention rate of the fluoride-containing primer was 50%. In the current study, the median, 28%, is a more reliable estimate to statistically report. It should be noted that the sample size was only five for the evaluation of

primer retention, and the results were not normally distributed. Also, despite the differences in the primer retention rates, both studies were in agreement that there was no association between primer retention and the number of days the teeth were in the mouth. In another in vivo study by Booth et al.³⁵, the retention rates were found to decrease by approximately 23% after 3 months, with a mean percent primer coverage of 56%, supporting the claim of reduction in the protective effects of this fluoride-containing primer. London et al.³¹ noted that reapplication of the fluoride-containing primer does not help combat wear or reestablish protection, further supporting the claim that the protective effects diminish after 3 months and that multiple applications do not add additional efficacy for prevention.³⁶ Based on these findings and those of our study, it seems that fluorescence testing to check the amount of primer covering the tooth surface should be done at every visit and the product should be re-applied as needed, not necessarily just at 3-month intervals. Future studies with a large sample size are needed to further investigate the retention rate of fluoride-containing primers and to correlate the surface coverage of the primer to its efficacy for minimizing demineralization.

The fluoride-containing primer also seemed to have no effect on the quality of the enamel on teeth subjected to interproximal reduction. No detectable differences could be visualized or measured on the micro-CT images suggesting that approximately 0.2mm of interproximal reduction performed with abrasive strips does not noticeably roughen the enamel surface, and therefore makes it susceptible to demineralization. This finding supports the notion that there are no long term adverse effects of interproximal reduction,²⁷ while disagreeing with claim that IPR roughens the enamel surface making it more plaque-retentive.²⁸ However, one needs to be cautious as these studies are not directly comparable due to the differences in the study designs.

The limitations of the current study include difficulty in patient enrollment in an academic setting, multiple bracket types used, multiple doctors treating patients, and varying lengths of time the teeth were in the oral environment. The undeniable fact that is consistent amongst most WSL studies,^{1,4,5,7} including the current one, is that there is an increase in the incidence of WSLs with orthodontic treatment in the absence of adequate oral hygiene. Therefore, further studies are warranted with a larger sample size, one operator, one bracket type, and a better controlled treatment time to control for confounding variables.

Also, although operator agreement was great, the process of detecting the lesions was tedious and subject to bias. The lesions were very superficial, making them difficult to detect and measure. Operators had to look very closely to even note the presence of enamel demineralization on the 3D micro-CT image (Figure 3) and then had to visually determine the deepest slice on the 2D images (Figure 4) by scrolling through the slices in the region of interest. Lesions less than 30 microns could not be measured with the tool used. The process of obtaining micro-CT images was also very timely and costly.

Conclusion

Within the limitations of this study, fluoride-containing primers do not seem to provide additional benefits over traditional primers in preventing demineralization in orthodontic patients.

Tables

Table 1: Association between Patient Factors and Presence of Lesion

	Visual Examination			Micro-CT		
	Y	N	P-value*	Y	N	P-value*
Treatment			1.0000			0.5765
Fluoride primer	8 (89%)	1 (11%)		8 (89%)	1 (11%)	
Control primer	8 (89%)	1 (11%)		6 (67%)	3 (33%)	
Handedness			1.0000			0.5765
Yes	8 (89%)	1 (11%)		8 (89%)	1 (11%)	
No	8 (89%)	1 (11%)		6 (67%)	3 (33%)	
Oral Hygiene			0.1373			0.7804
Good	4 (66%)	2 (33%)		4 (66%)	2 (33%)	
Fair	8 (100%)	0 (0%)		7 (88%)	1 (13%)	
Poor	4 (100%)	0 (0%)		3 (75%)	1 (25%)	
Time in Mouth (median, IQR)	67 (67-67)	99 (69.5- 158.5)	0.2987	76 (58-144)	99.5 (67- 114)	0.5601

*p-value from Fisher's Exact test or Wilcoxon rank-sum test as appropriate

Table 2: Summary of Lesion Depth for Each Study Subject

Subject	Depth at Deepest (μm)	
	Fluoride-Containing Primer	Control Primer
1	31.6	0
2	118.65	229.4
3	102.8	0
4	0	51.45
5	51.45	39.6
8	59.35	71.2
9	130.5	59.35
11	71.2	245.25
12	71.2	0

Table 3: Summary of Lesion Depth by Treatment

	Mean(μm)	Median(μm)	Range(μm)
Fluoride-Containing Primer	70.8	71.2	0-130.5
Control Primer	77.4	51.5	0-245.3
Paired Difference (Control-Fluoride Containing)	6.6	-11.9	-102.8-174.1

Figures

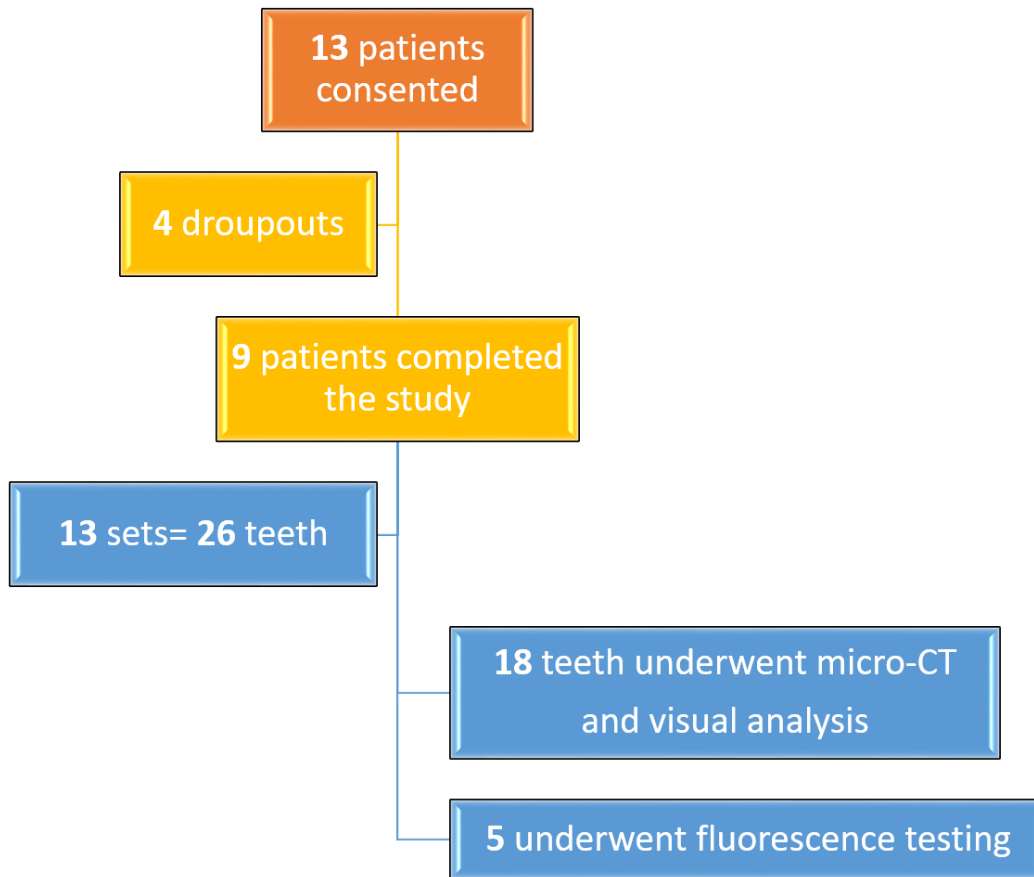


Figure 1: Patient Enrollment and Final Sample Size

Please check single best response:

- 1) Which is your dominant hand?
 - a. Right
 - b. Left
 - c. Both

- 2) What times of day do you usually snack? Check all that apply.
 - a. Morning
 - b. Afternoon
 - c. Evening
 - d. Night
 - e. Throughout the day
 - f. Never/rarely

- 3) How often do you drink juice, soda, or any sugar-containing beverage?
 - a. Daily
 - b. Occasionally
 - c. Rarely
 - d. Never

- 4) When do you typically drink juice, soda, or any sugar-containing beverage? Check all that apply.
 - a. Morning
 - b. Afternoon
 - c. Evening
 - d. Night
 - e. Throughout the day
 - f. Never/rarely

- 5) Please select your primary source(s) of water (check all that apply):
 - a. City water
 - b. Well water (fluoridated)
 - c. Well water (not-fluoridated)
 - d. Bottle water
 - e. Unsure

- 6) What type of tooth paste do you primarily use (check all that apply)?
 - a. Over-the-counter (fluoridated)
 - b. Over-the-counter (not-fluoridated)
 - c. Prescription toothpaste
 - d. Unsure
 - e. Not applicable

- 7) What type of mouth rinse do you primarily use (check all that apply)?
 - a. Over-the-counter (fluoridated)
 - b. Over-the-counter (not-fluoridated)
 - c. Prescription mouth rinse
 - d. Unsure
 - e. Not applicable

Figure 2: Research Participant Questionnaire

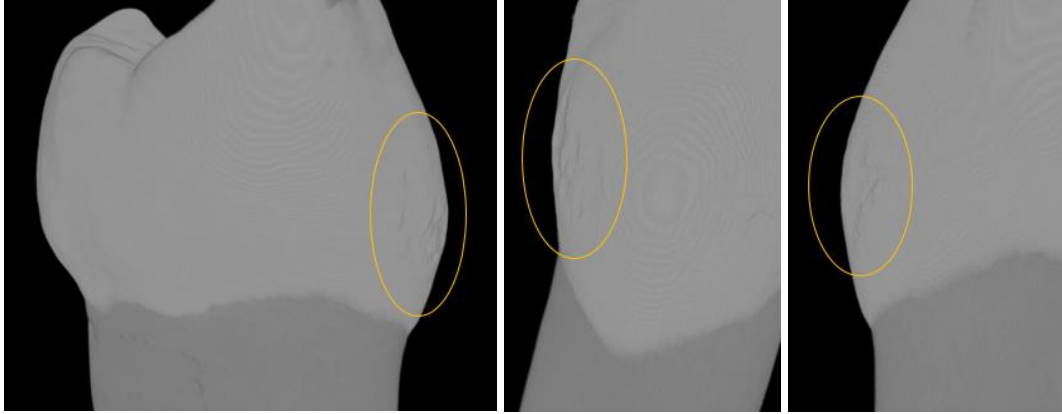


Figure 3: 3D Micro-CT Images of a Sample of Teeth with Enamel Demineralization. Surface roughness can be visualized.

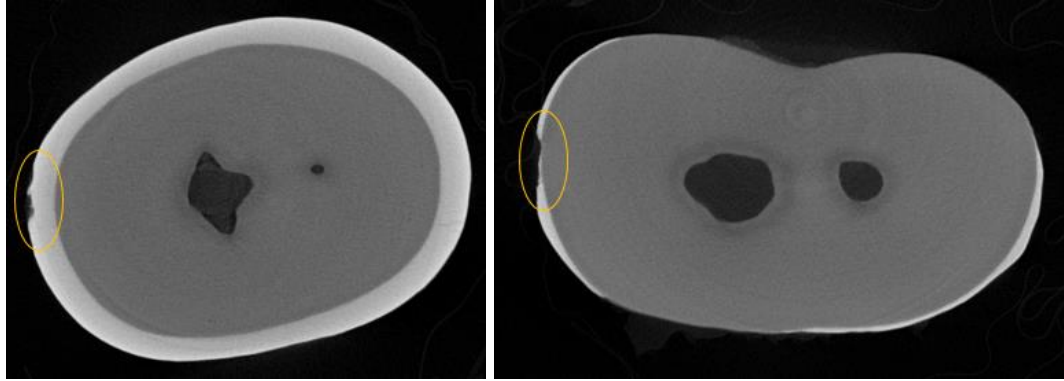


Figure 4: 2D Micro-CT Images of a Sample of Teeth with Enamel Demineralization. Axial slice of the deepest lesion that was measured for these two samples can be seen.

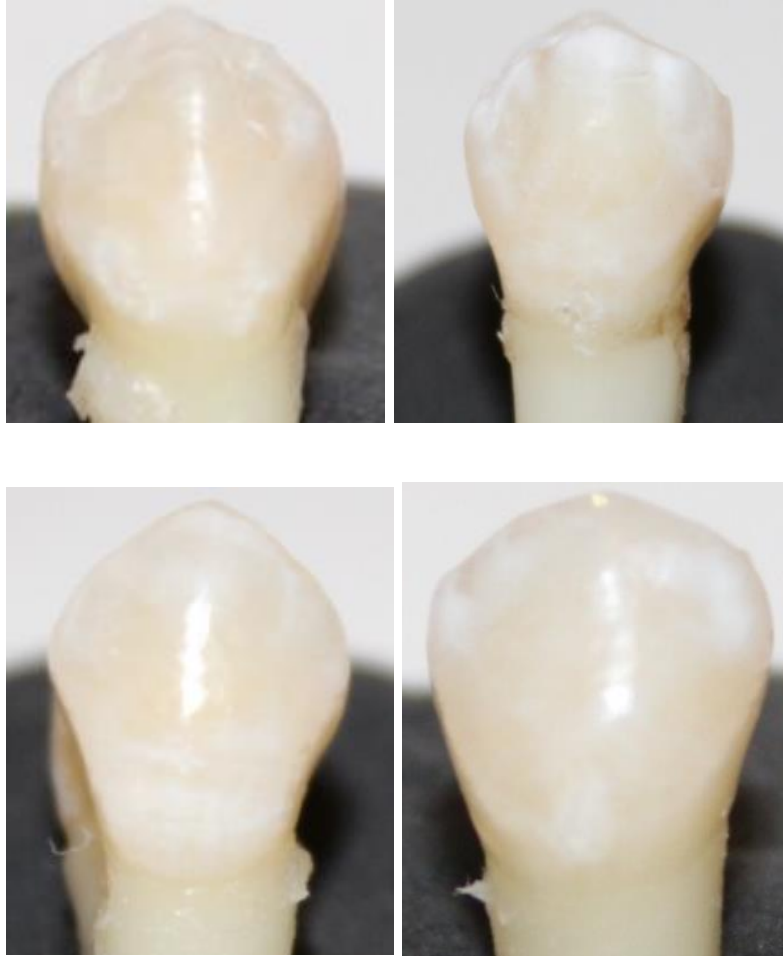


Figure 5: Photographs of a Sample of Teeth that Developed White Spot Lesions

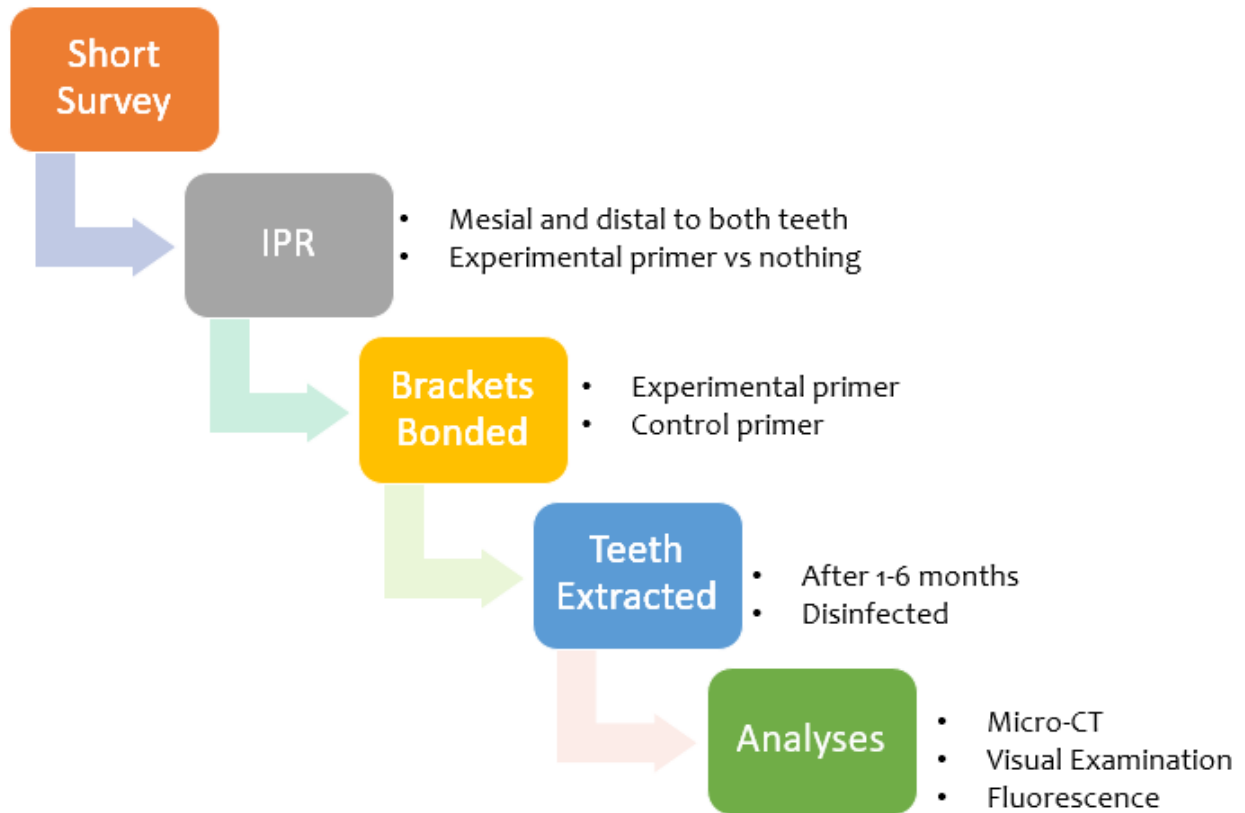


Figure 6: Methods Workflow

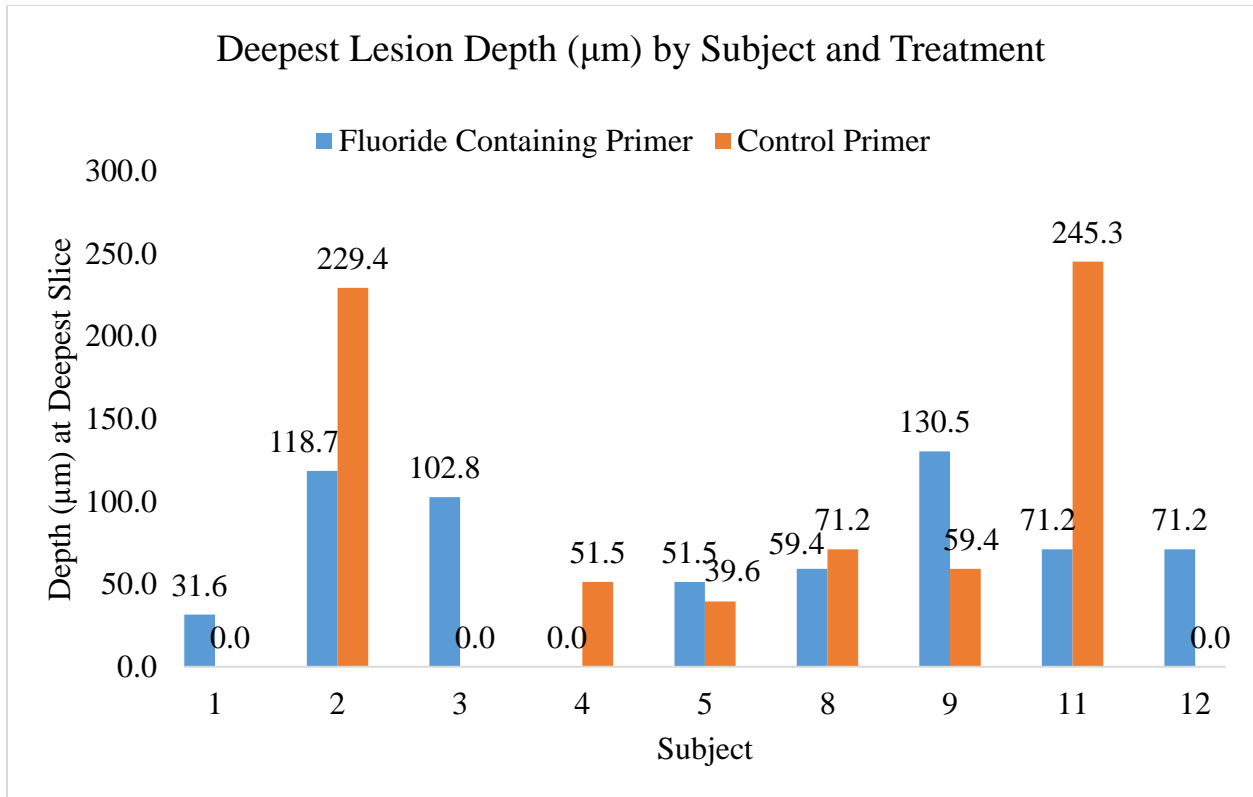


Figure 7: Summary of Lesion Depth for Each Study Subject

References

1. Chapman JA, Roberts WE, Eckert GJ, Kula KS, González-Cabezas C. Risk factors for incidence and severity of white spot lesions during treatment with fixed orthodontic appliances. *Am. J. Orthod. Dentofacial Orthop.* 2010;138(2):188–94. doi:10.1016/j.ajodo.2008.10.019
2. Sudjalim TR, Woods MG, Manton DJ. Prevention of white spot lesions in orthodontic practice: a contemporary review. *Aust. Dent. J.* 2006;51(4):284–9.
3. Tufekci E, Dixon JS, Gunsolley JC, Lindauer SJ. Prevalence of white spot lesions during orthodontic treatment with fixed appliances. *Angle Orthod.* 2011;81(2):206–10. doi:10.2319/051710-262.1
4. Gorelick L, Geiger AM, Gwinnett AJ. Incidence of white spot formation after bonding and banding. *Am. J. Orthod.* 1982;81(2):93–8.
5. Mizrahi E. Enamel demineralization following orthodontic treatment. *Am. J. Orthod.* 1982;82(1):62–7.
6. Ogaard B, Rølla G, Arends J. Orthodontic appliances and enamel demineralization. Part 1. Lesion development. *Am. J. Orthod. Dentofacial Orthop.* 1988;94(1):68–73.
7. Ogaard B. Prevalence of white spot lesions in 19-year-olds: a study on untreated and orthodontically treated persons 5 years after treatment. *Am. J. Orthod. Dentofacial Orthop.*

1989;96(5):423–7.

8. Hadler-Olsen S, Sandvik K, El-Agroudi MA, Ogaard B. The incidence of caries and white spot lesions in orthodontically treated adolescents with a comprehensive caries prophylactic regimen--a prospective study. *Eur. J. Orthod.* 2012;34(5):633–9.

9. Richter AE, Arruda AO, Peters MC, Sohn W. Incidence of caries lesions among patients treated with comprehensive orthodontics. *Am. J. Orthod. Dentofac. Orthop.* 2011;139(5):657–64. doi:10.1016/j.ajodo.2009.06.037

10. Ogaard B, Rølla G, Arends J, ten Cate JM. Orthodontic appliances and enamel demineralization. Part 2. Prevention and treatment of lesions. *Am. J. Orthod. Dentofacial Orthop.* 1988;94(2):123–8.

11. Farhadian N, Miresmaeili A, Eslami B, Mehrabi S. Effect of fluoride varnish on enamel demineralization around brackets: an in-vivo study. *Am. J. Orthod. Dentofacial Orthop.* 2008;133(4 Suppl):S95-8. doi:10.1016/j.ajodo.2006.09.050

12. Benson PE, Parkin N, Dyer F, Millett DT, Furness S, Germain P. Fluorides for the prevention of early tooth decay (demineralised white lesions) during fixed brace treatment. Benson PE. *Cochrane Database Syst. Rev.* 2013;(12):CD003809. doi:10.1002/14651858

13. Geiger AM, Gorelick L, Gwinnett AJ, Benson BJ. Reducing white spot lesions in orthodontic populations with fluoride rinsing. *Am. J. Orthod. Dentofacial Orthop.* 1992;101(5):403-7.

14. Benson PE, Shah AA, Millett DT, Dyer F, Parkin N, Vine RS. Fluorides, orthodontics and demineralization: a systematic review. *J. Orthod.* 2005;32(2):102–14. doi:10.1179/146531205225021033

15. Todd MA, Staley RN, Kanellis MJ, Donly KJ, Wefel JS. Effect of a fluoride varnish on demineralization adjacent to orthodontic brackets. *Am. J. Orthod. Dentofacial Orthop.* 1999;116(2):159–67.
16. Weyant RJ, Tracy SL, Anselmo TT, et al. Topical fluoride for caries prevention: executive summary of the updated clinical recommendations and supporting systematic review. *J. Am. Dent. Assoc.* 2013;144(11):1279–91.
17. Zachrisson BU, Heimgård E, Ruyter IE, Mjör IA. Problems with sealants for bracket bonding. *Am. J. Orthod.* 1979;75(6):641–9.
18. Ceen RF, Gwinnett AJ. Microscopic evaluation of the thickness of sealants used in orthodontic bonding. *Am. J. Orthod.* 1980;78(6):623–9.
19. Joseph VP, Rossouw PE, Basson NJ. Some “sealants” seal--a scanning electron microscopy (SEM) investigation. *Am. J. Orthod. Dentofacial Orthop.* 1994;105(4):362–8.
20. Frazier MC, Southard TE, Doster PM. Prevention of enamel demineralization during orthodontic treatment: An in vitro study using pit and fissure sealants. *Am. J. Orthod. Dentofacial Orthop.* 1996;110(5):459–65.
21. Buren JL, Staley RN, Wefel J, Qian F. Inhibition of enamel demineralization by an enamel sealant, Pro Seal: an in-vitro study. *Am. J. Orthod. Dentofacial Orthop.* 2008;133(4 Suppl):S88-94. doi:10.1016/j.ajodo.2007.01.025
22. Leizer C, Weinstein M, Borislow AJ, Braitman LE. Efficacy of a filled-resin sealant in preventing decalcification during orthodontic treatment. *Am. J. Orthod. Dentofacial Orthop.* 2010;137(6):796–800. doi:10.1016/j.ajodo.2008.11.025

23. Hu W, Featherstone JDB. Prevention of enamel demineralization: an in-vitro study using light-cured filled sealant. *Am. J. Orthod. Dentofacial Orthop.* 2005;128(5):592–600; quiz 670.
24. Anon. Opal Seal Website.
<https://www.ultradent.com/products/procedures/orthodontics/orthodontic-bracket-bonding/prime-and-seal/opal-seal>. Retrieved on August 20, 2017.
25. Tüfekçi E, Pennella DR, Mitchell JC, Best AM, Lindauer SJ. Efficacy of a fluoride-releasing orthodontic primer in reducing demineralization around brackets: An in-vivo study. *Am. J. Orthod. Dentofac. Orthop.* 2014;146(2):207–14. doi:10.1016/j.ajodo.2014.05.016.
26. Bartels AA, Evans CA, Viana G, Bedran-Russo AK. Demineralization of resin-sealed enamel by soft drinks in a clinically relevant pH cycling model. *Am. J. Dent.* 2016;29(2):115–9.
27. Zachrisson BU, Nyøygård L, Mobarak K. Dental health assessed more than 10 years after interproximal enamel reduction of mandibular anterior teeth. *Am. J. Orthod. Dentofacial Orthop.* 2007;131(2):162–9. doi:10.1016/j.ajodo.2010.09.002
28. Giulio AB, Matteo Z, Serena IP, Silvia M, Luigi C. In vitro evaluation of casein phosphopeptide-amorphous calcium phosphate (CPP-ACP) effect on stripped enamel surfaces. A SEM investigation. *J. Dent.* 2009;37(3):228–32. doi:10.1016/j.jdent.2008.11.015
29. Hellak AF, Riepe EM, Seubert A, Korbmacher-Steiner HM. Enamel demineralization after different methods of interproximal polishing. *Clin. Oral Investig.* 2015;19(8):1965–72. doi:10.1007/500784-015-1429-0.
30. Alexander SA, Ripa LW. Effects of Self-Applied Topical Fluoride Preparations in Orthodontic Patients. *Angle Orthod.* 2000;70(6):424-30.

31. London DM. (2017) In-vivo Assessment and Comparison of White Spot Lesions in Conventional Bonding Versus the Use of a Highly Filled Orthodontic Sealant: A Prospective, Randomized Clinical Controlled Trial. (Unpublished Master's Thesis, The University of Oklahoma College of Dentistry, Oklahoma City, OK)
32. Özgöz M, Arabaci T, Sümbüllü MA, Demir T. Relationship between handedness and toothbrush-related cervical dental abrasion in left- and right-handed individuals. *J. Dent. Sci.* 2010;5(4):177–82. doi:10.1016/j.jds.2010.11.001
33. Çakur B, Yildiz M, Dane S, Zorba Y. The effect of right or left handedness on caries experience and oral hygiene. *J. Neurosci. Rural Pract.* 2011;(2):40-2. doi:10.4103/0976-3147.80093
34. Oz AZ, Oz AA, Yazicioglu S. In vivo effect of antibacterial and fluoride-releasing adhesives on enamel demineralization around brackets: A micro-ct study. *Angle Orthod.* 2017;87(6):841–6. doi:10.2319/060217-371.1
35. Booth N. (2015) In Vivo Retention of a Glass-Ionomer Containing, Nano-Filled Orthodontic Sealant. A Prospective, Randomized Clinical Controlled Trial Assessing Sealant Longevity. (Unpublished Master's Thesis, The University of Oklahoma College of Dentistry, Oklahoma City, OK)
36. Basdra EK, Huber H, Komposch G. Fluoride released from orthodontic bonding agents alters the enamel surface and inhibits enamel demineralization in vitro. *Am. J. Orthod. Dentofacial Orthop.* 1996;109(5):466–72.

